



Multispecies marine fish mortality linked to cowfish toxicosis

Goodall A.M.¹, Armwood A.R.¹, Semple L.², Sundin N.², Thomas R.²,
Lewbart G.A.^{1*}

Received: July 2025

Accepted: September 2025

Abstract

Cowfish, also known as boxfish or trunkfish, are species commonly displayed in public aquaria due to their unique shape and charismatic nature. However, when stressed, these animals can secrete a powerful and potentially fatal toxin from their skin. In one such instance, it is believed that toxin released from a honeycomb cowfish (*Acanthostracion polygonius*) was responsible for a large-scale mortality event resulting in the death of itself and 19 other fish species in a closed quarantine system.

Keywords: Boxfish, cowfish, *Acanthostracion polygonius*, Ostraciidae, Toxicity, Praziquantel, Ostracitoxin, Pahutoxin

1- North Carolina State University College of Veterinary Medicine, Raleigh North Carolina, USA

2-SEALiFE Concord, Concord North Carolina, USA

*Corresponding author's Email: galewbar@ncsu.edu

Introduction

The trunkfish family, Ostraciidae, belongs to the order Tetraodontiformes and includes small to medium-sized marine fishes commonly known as boxfish, cowfish, and trunkfish. They are found primarily in tropical and subtropical oceans around coral reefs and lagoons. They have a square, triangular, or rounded appearance and usually grow up to 40 cm (16 in) in length, though sizes vary by species.

Trunkfish are notable for their rigid, box-like body encased in a hard, bony carapace made up of fused plates. These tessellated, mineralized plates (or “scutes”) create a protective shell that limits their flexibility but shields them from predators (Eigen *et al.*, 2022). Many species within the Ostraciidae can further deter predation through secreting toxic substances from their skin, referred to as ostracitoxin or pahutoxin. This repellent substance is a hemolytic ichthyotoxin, causing exposed fish to demonstrate gasping, loss of balance, convulsions, and death in other species, with even the boxfish itself reported to become moribund in scenarios where the toxin is at high concentrations (Thomson, 1964). In contrast, their relatives the pufferfish are immune to their own tetrodotoxin due to a mutation which prevents binding of the toxin to their nerve cells (Venkatesh *et al.*, 2005; Nagashima *et al.*, 2018; Katikou *et al.*, 2022).

Pahutoxin has been established as a choline chloride ester of 3-acetoxyhexadecanoic acid, functioning similarly to the saponins of echinoderms

(Boylan and Scheuer, 1967). With a structure similar to quaternary ammonium cationic detergents, it was postulated that the toxin’s lethality was linked to this detergent-like structure (Kalmanzon and Zlotkin, 2000). However, additional research demonstrated that the ichthyotoxic nature of the trunkfish substance is receptor-mediated rather than due to its surfactant properties, targeting receptors specific to gill membranes (Kalmanzon *et al.*, 2004). Furthermore, preliminary studies have demonstrated that the trunkfish differs in the gill membrane composition that pahutoxin binds to, suggesting that trunkfish may be somewhat tolerant to their own toxin (Kalmanzon *et al.*, 2003).

In addition to probable tolerance, it is presumed that in the wild, boxfish are able to escape from its own expelled toxin. Unfortunately, when under human care in a confined life support system, this behavior can be toxic for all inhabitants, including the trunkfish itself (Thomson, 1964). Anecdotal accounts of aquarium mortalities due to cowfish have been reported, as well as several incidents of human toxicity following ingestion of Ostraciidae species (Taniyama *et al.*, 2009). Symptoms of boxfish poisoning in humans closely resemble those of palytoxin poisoning from parrotfish (*Scarus ovifrons*), including rhabdomyolysis resulting in severe muscle pain, black urine, and significantly increased serum creatine phosphokinase (Taniyama *et al.*, 2009). At least one human death has been documented following consumption of a

cowfish (*Lactoria diaphana*) that led to rhabdomyolysis and cardiopulmonary arrest (Shinzato *et al.*, 2008).

Materials and methods

Several dozen fish, including a honeycomb cowfish (*Acanthostracion polygonius*), were packaged and shipped overnight from Dynasty Marine in South Florida to SEA LIFE Aquarium in North Carolina. The animals each arrived in their own insulated bag, with no notable concerns upon receipt. Each fish was inspected at arrival to ensure health and account for shipping inventory. As part of the acclimation process, the fish were unpacked in the dark to reduce stress and moved into appropriately sized containers, grouped for their size or temperament. Water from the SEALIFE quarantine system was slowly dripped into each container of fish, with the cowfish initially being isolated by itself due to the species' potential for toxin secretion.

The fish were ultimately divided into three tanks by size and temperament: large fish (including the honeycomb cowfish) in the front, medium-sized fish in a rear tank, and the smallest fish in a center rectangular tank. These three tanks drained into a shared sump, from which water was pumped and circulated into, allowing water and gas to flow freely between each of the tanks. The animals appeared to be adjusting appropriately and eating. A prophylactic praziquantel treatment series was initiated with the goal of three treatments total of 4 parts per million each. Additional aeration was provided to

each tank, as well as an oxygen tank with air stones lightly bubbling on the system to keep oxygen levels up. Due to anecdotal reports of praziquantel causing bacterial blooms and resultant dissolved oxygen (DO) depletion, DO was monitored several times a day. This idea is further substantiated by the suggestion that praziquantel may be used as an energy source by microbial populations following exposure (Thomas *et al.*, 2016).

Praziquantel was dissolved in about 100 mL of grain (95%) alcohol before being added to the system due to otherwise poor solubility in water. Once thoroughly mixed on a mix plate, tank water was introduced to a fill volume of about 3L. The solution was poured into one of the filter socks in the system sump so that any non-dissolved praziquantel would be caught in the sock.

The medication was administered in the morning in order for aquarium staff to monitor the animals and the system throughout the day. Aeration and oxygen input was increased for the overnight hours, aiming for a saturation level of 100-120% DO. Following the initial praziquantel treatment, all fish looked stable with no concerns. A large water change of approximately 50% was performed the morning following praziquantel administration, in addition to siphoning of the bottom of the tanks. Supplemental oxygen was removed, however the air stones remained running at a high level in the system to address any potential bacterial bloom.

One week after the first treatment, the second dose of 4ppm praziquantel

treatments was added to the system. The fish initially appeared stable throughout the day, however upon arrival the next morning, the tanks were exceptionally cloudy. The entire population of the front tank (large individuals including the cowfish) was determined to be deceased. In addition, the sump of the tank was overflowing with foamy bubbles, and aquarium staff noted an abnormal, chemical smell coming from the system. Upon further assessment, the DO level was approximately 95% with oxygen still flowing. It was determined that most of the animals in the tanks had died (Table 1), with the exception of the green razor wrasse (*Iniistius* sp.) and

slippery dick wrasse (*Halichoeres bivittatus*) which were laterally recumbent and moribund, but operculating slightly. Deceased individuals were removed and placed into a necropsy freezer, and a substantial water change was performed. In the following days, the two wrasses became more alert, swimming sporadically, and eventually making a full recovery. It was elected to forego the third praziquantel treatment, and the surviving wrasses completed quarantine introduced onto exhibits where they have continued to appear systemically stable and healthy, over 1 year later.

Table 1: Animals found deceased at the time of incident (suspected due to *Acanthostracion polygonius* toxin exposure).

Species	Common Name	Number of Individuals
<i>Acanthemblemaria spinosa</i>	Spinyhead blenny	1
<i>Acanthostracion polygonius</i>	Honeycomb cowfish	1
<i>Acanthurus coeruleus</i>	Blue tang	4
<i>Amblycirrhitus pinos</i>	Redspotted hawkfish	1
<i>Apogon maculatus</i>	Flamefish	10
<i>Arothron meleagris</i>	Guineafowl pufferfish	1
<i>Centropyge argi</i>	Cherub pygmy Angelfish	1
<i>Chaetodon capistratus</i>	Foureye butterflyfish	2
<i>Chromis cyanea</i>	Blue chromis	9
<i>Gnatholepis thompsoni</i>	Goldspot goby	1
<i>Halichoeres radiatus</i>	Puddingwife wrasse	2
<i>Mulloidichthys martinicus</i>	Yellow goatfish	5
<i>Priolepis hipoliti</i>	Rusty Goby	1
<i>Pterois volitans</i>	Red lionfish	4
<i>Serranus tabacarius</i>	Tobcaccofish	1
<i>Serranus tortugarum</i>	Chalk bass	4
<i>Sphoeroides spengleri</i>	Bandtail puffer	1
<i>Thalassoma lucasanum</i>	Cortez rainbow wrasse	1
<i>Tigrigobius macrodon</i>	Tiger goby	1
<i>Xanthichthys ringens</i>	Sargassum triggerfish	2

Results

On gross necropsy, abundant white mucus covered the skin of the cowfish (Fig. 1), and other affected fish from the system. No significant findings or an underlying etiology for the widespread

fatalities were noted on gross internal inspection of the carcasses that were examined. Gill tissue was submitted for histologic evaluation from fish affected by the mortality event. The samples were autolyzed at the time of evaluation.

Microscopic findings of the gills exhibited epithelial cells lifting from the underlying pillar cells in most lamellae (Fig. 2). This epithelial lifting was interpreted as likely artificial due to

delayed fixation, but it can be indicative of a true lesion such as poor water quality or toxic exposure (Wolf *et al.*, 2014).

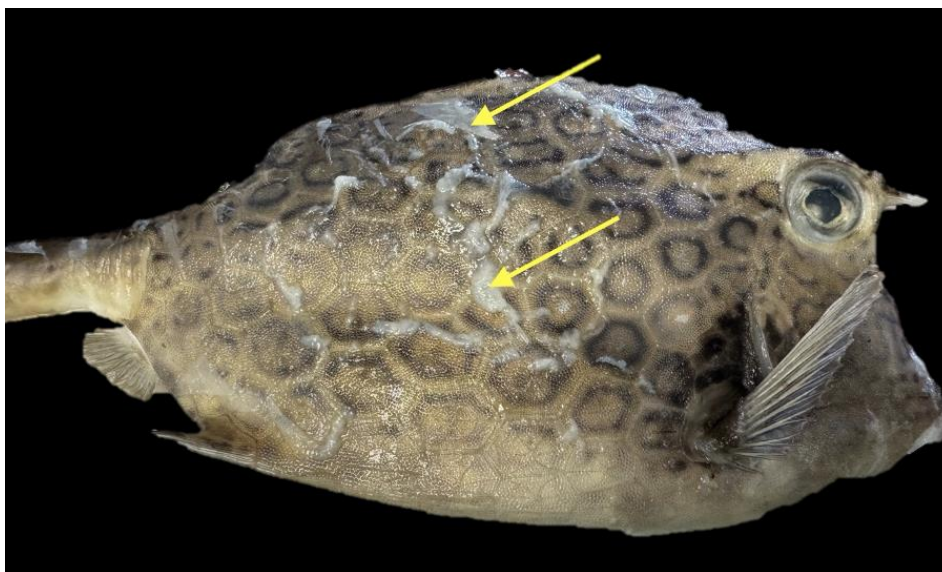


Figure 1: Several of the deceased fish after being thawed for gross necropsy. Note the excessive amount of mucus (arrows) on the deceased cowfish (*Acanthostracion polygonius*).

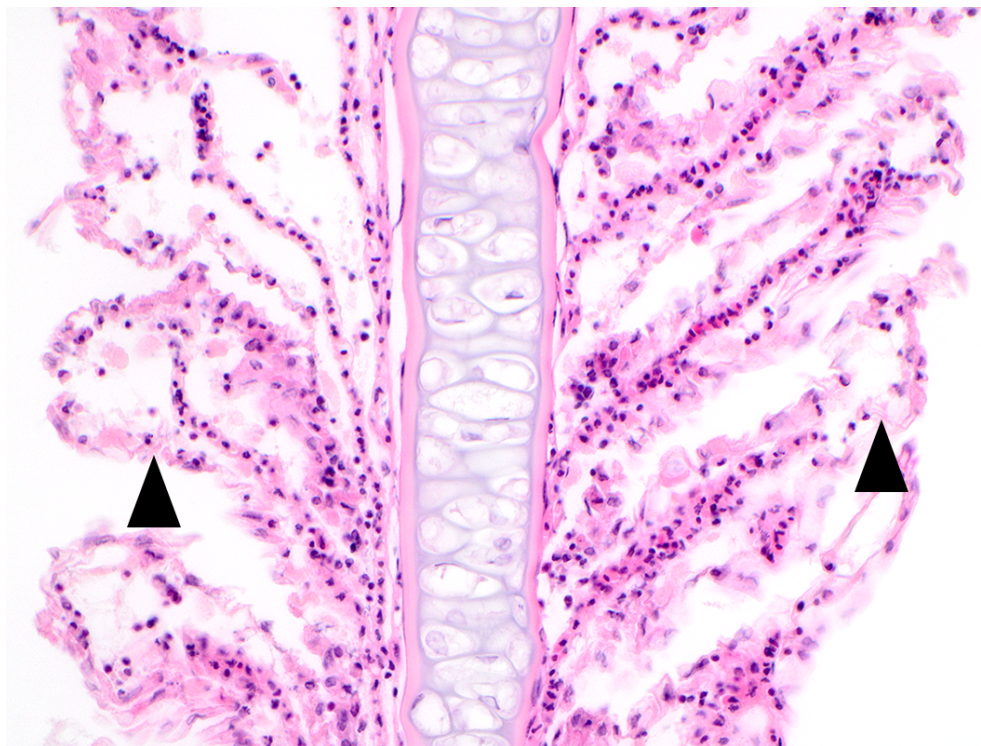


Figure 2: A photomicrograph of a gill filament with associated lamellae demonstrates lifting of the epithelial cells from the underlying pillar cells on multiple lamellae (arrowheads). Occasionally this space contains cellular debris. This histologic finding can occur with suboptimal water quality, toxin exposure, or autolysis due to delayed fixation.

Other supportive lesions of acute to peracute branchial disease in the cowfish were absent. More definitive indicators of acute gill injury (such as lamellar thrombosis) or more subacute to chronic branchial disease (such as lamellar fusion, goblet cell hyperplasia, or epithelial hyperplasia) were not identified. While acute or chronic branchial disease was largely ruled out, peracute injury could not be definitively ruled in or out with the coinciding autolysis. Overall, the gill histologic examination did not reveal a definitive cause of death or other evidence of disease (e.g., protozoa, monogeneans) in the cowfish.

Discussion

The findings of this mortality event strongly suggest the affected animals succumbed to ichthyotoxin produced by the honeycomb cowfish (*Acanthostracion polygonius*). As reported in the literature, a distressed trunkfish can release a whitish foamy secretion (Bell *et al.*, 1994). Given the abundance of mucus present on the cowfish post-mortem, paired with the large amount of foam and distinct chemical smell reported in the sump during the SEALIFE mortality event, it is suggested that the cowfish, whether in life or death, emitted toxin resulting in the death of numerous species within the same quarantine water system.

There are several factors still in question regarding this mortality event. Perhaps most notably is that although a sample of the mucus was obtained, it has not been chemically analyzed at this

time as a laboratory has not been identified to evaluate the sample. In understanding that cowfish have a relative decrease in gill membrane receptors that bind their own ichthyotoxin (Kalmazon *et al.*, 2003) compared to other fish species suggests that cowfish are less susceptible to the toxin. It is unclear in the current case whether the fish was already deceased at the time of toxin release, or if the toxin in the system was so elevated that the otherwise resistant fish experienced a dose superseding its innate tolerance, resulting in lethality. Further studies to establish lethal doses of this particular toxin by species would be warranted given the demise of the cowfish itself, as well as the peculiar nature that two wrasses in the system survived the toxin release.

If the cowfish was alive at the time of toxin release, it is likely the animal became stressed in some capacity. While unknown for this particular event, examples of potential cause could include changes in water parameters such as transient low dissolved oxygen. It is arguably less likely that the praziquantel treatment attributed to the animal's suspected distress and ultimate toxin release, as the initial treatment was performed uneventfully using the same dose of drug.

Further research to assess human risk when working with these animals would be pertinent to ensure safety of individuals handling these species. While the risk would presumably be less for those working with these animals in public aquaria compared to the

published case of a human dying from cowfish ingestion (Shinzato *et al.*, 2008), it nonetheless poses a concern and should be explored. Further, while dermal absorption itself is a less common route of exposure, an article evaluating human exposure to quaternary ammonium compounds (QACs) found that hand-to-mouth contact accounted for >90% of post-application exposure (Li *et al.*, 2020).

On a larger scale, extensive use of quaternary ammonium detergents could prove detrimental to marine life given the similar structure to the trunkfish toxin. Quaternary ammonium compounds are surfactants that contain a positive nitrogen atom attached to at least one hydrophobic hydrocarbon, and are utilized for their bacterial, viral, and fungi killing properties. Use of products containing quaternary ammonium compounds (QACs) have increased since the COVID-19 pandemic, and raw sewage is reported to have high concentrations of QACs (Mohapatra *et al.*, 2023). In areas where seawater is polluted with these detergents, there should be concern for fish exhibiting similar clinical signs of the affected fish in this mortality event (increased operculating, lateral recumbency, and death).

Overall, given the potential for significant animal loss, it is recommended to quarantine and treat Ostraciidae separately from other fish in a fully closed system. Furthermore, the knowledge that the cowfish may succumb to its own toxin lends itself to the recommendation that even singularly

housed cowfish should be regularly monitored for signs of stress to mitigate possible expulsion of toxin within their own system.

References

- Bell, R., Carmeli, S. and Sar, N., 1994.** Vibrindole A, a metabolite of the marine bacterium, *Vibrio parahaemolyticus*, isolated from the toxic mucus of the boxfish *Ostracion cubicus*. *Journal of Natural Products*, 57(11), 1587–1590. <https://doi.org/10.1021/np50113a022>
- Boylan, D.B. and Scheuer, P.J., 1967.** Pahutoxin: A fish poison. *Science*, 155(3758), 52–56. <https://doi.org/10.1126/science.155.3758.52>
- Eigen, L., Baum, D., Dean, M.N., Werner, D., Wölfer, J. and Nyakatura, J.A., 2022.** Ontogeny of a tessellated surface: Carapace growth of the longhorn cowfish *Lactoria cornuta*. *Journal of Anatomy*, 241(3), 565–580. <https://doi.org/10.1111/joa.13692>
- Kalmanzon, E. and Zlotkin, E., 2000.** An ichthyotoxic protein in the defensive skin secretion of the Red Sea trunkfish *Ostracion cubicus*. *Marine Biology*, 136(3), 471–476. <https://doi.org/10.1007/s002270050706>
- Kalmanzon, E., Rahamim, Y., Barenholz, Y., Carmeli, S. and Zlotkin, E., 2003.** Receptor-mediated toxicity of pahutoxin, a marine trunkfish

- surfactant. *Toxicon*, 42(1), 63–71.
[https://doi.org/10.1016/s0041-0101\(03\)00101-6](https://doi.org/10.1016/s0041-0101(03)00101-6)
- Kalmanzon, E., Rahamim, Y., Carmeli, S., Barenholz, Y. and Zlotkin, E., 2004.** Endogenous regulation of the functional duality of pahutoxin, a marine trunkfish surfactant. *Toxicon*, 44(8), 939–942.
<https://doi.org/10.1016/j.toxicon.2004.07.029>
- Katikou, P., Gokbulut, C., Kosker, A. R., Campàs, M. and Ozogul, F., 2022.** An updated review of tetrodotoxin and its peculiarities. *Marine Drugs*, 20(1), 47.
<https://doi.org/10.3390/md20010047>
- Li, D., Sangion, A. and Li, L., 2020.** Evaluating Consumer Exposure to Disinfecting Chemicals against Coronavirus Disease 2019 (COVID19) and Associated Health Risks. *Environment International*, 145, 106108.
<https://doi.org/10.1016/j.envint.2020.106108>
- Mohapatra, S., Yutao, L., Goh, S.G., Ng, C., Luhua, Y., Tran, N.H. and Gin, K.Y.H., 2023.** Quaternary ammonium compounds of emerging concern: Classification, occurrence, fate, toxicity and antimicrobial resistance. *Journal of Hazardous Materials*, 445, 130393.
<https://doi.org/10.1016/j.jhazmat.2022.130393>
- Nagashima, Y., Ohta, A., Yin, X., Ishizaki, S., Matsumoto, T., Doi, H. and Ishibashi, T., 2018.** Difference in uptake of tetrodotoxin and saxitoxins into liver tissue slices among pufferfish, boxfish and porcupinefish. *Marine Drugs*, 16(1), 17.
<https://doi.org/10.3390/md16010017>
- Shinzato, T., Furuu, A., Nishino, T., Abe, K., Kanda, T., Maeda, T. and Kohno, S., 2008.** Cowfish (*Umisuzume lactoria diaphana*) poisoning with rhabdomyolysis. *Internal Medicine*, 47(9), 853–856.
<https://doi.org/10.2169/internalmedicine.47.0847>
- Taniyama, S., Sagara, T., Nishio, S., Kuroki, R., Asakawa, M., Noguchi, T., Yamasaki, S., Takatani, T. and Arakawa, O., 2009.** Survey of food poisoning incidents in Japan due to ingestion of marine boxfish, along with their toxicity. *Journal of the Food Hygienic Society of Japan (Shokuhin eiseigaku zasshi)*, 50(5), 270–277.
<https://doi.org/10.3358/shokueishi.50.270>
- Thomas, A., Dawson, M.R., Ellis, H. and Stamper, M.A., 2016.** Praziquantel degradation in marine aquarium water. *PeerJ*, 4.
<https://doi.org/10.7717/peerj.1857>
- Thomson, D.A., 1964.** Ostracitoxin: An ichthyotoxic stress secretion of the boxfish, *Ostracion lentiginosus*. *Science*, 146(3641), 244–245.
<https://doi.org/10.1126/science.146.3641.244>
- Venkatesh, B., Lu, S.Q., Dandona, N., See, S.L., Brenner, S. and Soong,**

- T.W., 2005.** Genetic basis of tetrodotoxin resistance in pufferfishes. *Current Biology*, 15(22), 2069–2072. <https://doi.org/10.1016/j.cub.2005.10.068>
- Wolf, J.C., Baumgartner, W.A., Blazer, V.S., Camus, A.C., Engelhardt J.A., Fournie, J.W., Frasca, S. Jr, Groman, D.B., Kent, M.L., Khoo, L.H., Law, J.M., Lombardini, E.D., Ruehl-Fehlert, C., Segner, H.E., Smith, S.A., Spitsbergen, J.M., Weber, K. and Wolfe, M.J., 2014.** Nonlesions, misdiagnoses, missed diagnoses, and other interpretive challenges in fish histopathology studies: a guide for investigators, authors, reviewers, and readers. *Toxicol Pathol.*, 43(3), 297-325.
DOI:10.1177/0192623314540229.
Epub 2014 Aug 11. PMID: 25112278.