



## Dietary oregano extract (*Origanum vulgare* L.) improves growth performance and alleviates histopathological alterations in the intestine and liver of koi fish (*Cyprinus carpio*) under long-term naproxen exposure

Jafari K.<sup>1</sup>; Mehdipour M.<sup>1\*</sup>; Firouzbakhsh F.<sup>2</sup>; Kazempoor R.<sup>3</sup>; Alavinejad Sh.<sup>4</sup>

Received: May 2025

Accepted: August 2025

### Abstract

Pharmaceutical contaminants in aquatic environments are an increasing ecological concern that adversely affect aquaculture production, resulting in reduced productivity and substantial economic losses. This study evaluated the protective role of oregano essential oil (OEO) supplementation on growth performance and histopathological changes in koi fish (*Cyprinus carpio*) subjected to long-term exposure to naproxen (NPX). A total of 180 fish were randomly assigned to four treatment groups: control, OEO-fed, NPX-exposed, and combined OEO-fed/NPX-exposed. The findings revealed that OEO supplementation significantly enhanced growth performance by increasing intestinal villus length and thickness, as well as the number of goblet cells, indicating improved nutrient absorption and intestinal health. In contrast, NPX exposure induced marked hepatic and intestinal lesions, such as villus corruption, vacuolation, hyperemia, villus adhesion, and cellular necrosis. Notably, these pathological alterations were substantially alleviated in the OEO-fed group, demonstrating the protective efficacy of OEO. Overall, dietary supplementation with OEO offers a promising natural strategy to counteract the adverse impacts of pharmaceutical pollutants on fish health, with potential benefits for sustainable aquaculture.

**Keywords:** Koi fish, Oregano essential oil, Naproxen, Growth performance, Histopathological changes

1- Department of Veterinary, Garmsar Branch, Islamic Azad University, Garmsar, Iran

2- Department of Fisheries, Faculty of Animal Science and Fisheries, Sari Agricultural Sciences and Natural Resources University (SANRU), Sari, Iran

3- Department of Veterinary Hygiene, SR.C., Islamic Azad University, Tehran - IRAN.

4- Department of Aquatic Health and Diseases, Faculty of Veterinary Medicine, University of Tehran, Tehran, Iran.

\*Corresponding author's Email: m.mehdipour@iau-garmsar.ac.ir

## Introduction

Today, pollutants are considered a major global health threat. The contamination of aquatic ecosystems with chemical pollutants has received increasing attention due to frequent identification and increased occurrence (Grabicová *et al.*, 2020; Picinini-Zambelli *et al.*, 2025). Human drugs are among the most significant, diverse, and effective new pollutants. Drug residues or their metabolites are usually detected in relatively low concentrations in the water environment of developed countries. These compounds have various adverse consequences, such as a reduction in growth, behavioral changes, sexual differentiation, and reproductive disorders in non-target organisms (Miller *et al.*, 2018; Sehonova *et al.*, 2018).

Nonsteroidal anti-inflammatory drugs (NSAIDs) are among the most widely used drugs in medicine and veterinary medicine, which are prevalent due to their relatively low cost, high effectiveness, and lack of alternatives (Whitfield-Cargile *et al.*, 2016). This problem has led to the entry of pharmaceutical residues into the surface and underground waters, causing pollution for non-target organisms, including aquatic animals (Madikizela and Ncube, 2021; Justi *et al.*, 2025).

Naproxen (NPX) is a commonly used drug belonging to the NSAID family, which is a dicyclic propionic acid derivative. Its mechanism of action is based on the inhibition of both isoforms of cyclooxygenase involved in the synthesis of prostaglandins,

prostacyclin, and thromboxane from arachidonic acid (Wojcieszynska and Guzik, 2020). NPX has fast absorption, a long duration of action, and a strong binding ability to plasma proteins. It can be purchased without a prescription, making it popular in the pharmaceutical market compared to other NSAIDs (Angiolillo and Weisman 2017; Aguilar *et al.*, 2019). Approximately 3000 tons of naproxen were produced worldwide in 2003 (Li *et al.*, 2016), and its high consumption has led to an increase in aquatic environments (Xu *et al.*, 2019). The decrease in the availability of nutrients has led to an increase in the price of feed used in aquaculture. Therefore, research has increased to find alternative resources with lower prices and better performance to achieve profitable and sustainable production (FAO, 2018). Plant derivatives or phytogenics, and plant extracts or phytobiotics, are compounds mainly obtained from aromatic plants and their essential oils. These compounds have a significant effect on improving the growth performance and immunity of fish (Abdel-Latif *et al.*, 2020; Kazempoor *et al.*, 2022; Gruber *et al.*, 2025). Oregano (*Origanum vulgare* L.) is a natural phytobiotic product, and its essential oils are mainly composed of carvacrol and thymol. Studies have reported the beneficial effects of whole oregano leaves, oregano extract press cake, or its essential oil (OEO) as effective food supplements in improving growth performance and health in different fish species (Abdel-Latif *et al.*, 2020).

It is indeed important to investigate the effects of exposure to pharmaceutical residues on fish, especially in aquaculture farms that use river water. Solutions to reduce the complications caused by poisoning should also be explored. The use of a diet containing supplements to improve metabolic and physiological functions and immune stimulants can be an effective approach. Plant essential oils, such as oregano essential oil (OEO), have been shown to be effective functional food supplements that can improve growth performance and health in fish (Kazempoor *et al.*, 2022). In this study, the effect of feeding with OEO was investigated on the growth performance, the structure of intestinal villi, and the occurrence of histopathological lesions in the intestine and liver of Koi fish after long-term exposure to NPX for the first time. This research contributes to understanding the potential of using natural supplements to mitigate the effects of pharmaceutical pollution in aquaculture and improve the health and growth of the fish.

### **Materials and methods**

#### *Origanum vulgare extract and preparation of experimental diets*

In this study, the OEO used was a commercial product from Pars Ayman Daru Company (Tehran, Iran), and it was added to the base diet at a ratio of 2 ml/kg. The essential oil was sprayed onto the commercial feed before each feeding. The fish used in the study were koi fish (*Cyprinus carpio*) with an average weight of  $5\pm 1$  g and an average

standard length of  $6\pm 1$  cm. They were purchased from an ornamental fish breeding center in Sari, Mazandaran, Iran, and were acclimated to laboratory conditions for two weeks. During this period, they were fed a basic commercial diet.

#### *Fish rearing condition*

The fish were then kept in fiberglass tanks with 15 liters of water each, with 15 fish in each tank and continuous aeration. They were divided into four treatments with three replications each: a group fed with the basic ration and not exposed to NPX; a group fed with a diet containing OEO and not exposed to NPX (OE); a group fed with the basal diet and exposed to NPX (NAP); and a group fed with a diet containing OEO and exposed to NPX (OE+NAP). The fish were fed their respective experimental diets twice a day (based on 5% of their body weight) for four consecutive weeks, with feeding times at 9:00 and 16:00. The light cycle was set to 12:12 hours of dark and light, and 30% of the aquarium water was siphoned daily to remove feces and unconsumed food and replaced with fresh water. At the end of the fourth week, the fish were exposed to NPX poisoning for 14 days. The study aimed to investigate the effects of OEO on the growth performance, intestinal villi structure, and the occurrence of histopathological lesions in the intestine and liver of koi fish exposed to NPX.

### *Long-term exposure to NPX*

The exposure of the fish to NPX was carried out in accordance with OECD guideline No. 204 (OECD, 1984). On the 30th day of the experiment, the fish were exposed to NPX (Razak Pharmaceutical Company, Tehran, Iran) for 14 days. To achieve this, 100 mg/L of NPX powder was added to the tank water every day after dissolving it in 10 ml of distilled water. To maintain the drug concentration, 70% of the water in the tanks was replaced with fresh water daily. Feeding with both diets was continued as before during the intoxication period. The aim of this step was to investigate the effects of NPX on

WG = (final weight - initial weight)

WG% = [(final weight - initial weight)/initial weight] × 100

SGR = [(ln final weight - ln initial weight)/days] × 100

### *Histopathological examination*

To investigate the effects of OEO supplementation and NPX exposure on the intestinal morphology and histopathology of the fish, intestinal morphometric examinations were performed on days 0, 30, 37, and 44, and pathological examinations were performed on days 30, 37, and 44 using three fish from each treatment. After euthanizing the fish with clove powder, the intestinal organs and liver were separated and fixed in 10% formalin. The samples were then dehydrated in an alcoholic solution with ascending concentrations and clarified in xylene to prepare histological slides. Tissue sections with a diameter of 5 microns were prepared using a microtome device and placed on slides. Hematoxylin-eosin (H&E) staining was performed, and

the fish and to evaluate the potential protective effects of OEO supplementation on the fish during NPX exposure.

### *Growth performance*

To evaluate the growth performance of the fish, the initial weight and final weight of the fish were recorded on days 0 and 30 of the experiment, respectively, for five fish specimens from each treatment. Based on this data, weight gain factor (WG), weight gain percentage (WG%), and specific growth rate (SGR) were calculated using formula (1) described by Abdel-Latif *et al.* (2020):

histological and pathological examinations were performed using light microscopy (Olympus BX51; Olympus, Tokyo, Japan) (Alavinezhad *et al.*, 2020).

### *Data analysis*

The normality of the data was assessed using the Kolmogorov-Smirnov test. To compare means and the relationship between the measured factors, the paired t-test was used at a significance level of 5%. Any significant differences between treatments were evaluated using one-way analysis of variance (One-way ANOVA). If significant differences were found, Duncan's test was used to compare means at a significance level of 0.05. All statistical analyses were performed using SPSS 21 and Excel 2013 software.

## Results

### Growth performance

Table 1 presents the results for the initial weight, final weight, WG, WG%, and SGR parameters. The initial weight of the fish showed no significant difference ( $p>0.05$ ) among the treatments. On the 30th day of the experiment, the final weight, WG, WG%, and SGR in the OE

and OE+NAP groups showed a significant increase compared to the CRT and NAP groups ( $p<0.05$ ). However, no significant differences were observed between the CRT and NAP groups, and between the OE and OE+NAP groups ( $p>0.05$ ) for any of the investigated factors.

**Table 1: Comparison of Growth Parameters (Mean±SE) in Four Experimental Groups of Koi Fish (*Cyprinus carpio*) (WG: Weight Gain; SGR: Specific Growth Rate)**

Growth parameters	Experimental group			
	C	OE	OE+NP	NP
Initial weight (mg)	5.58±0.08 <sup>a</sup>	5.66±0.05 <sup>a</sup>	5.6±0.09 <sup>a</sup>	5.52±0.06 <sup>a</sup>
Final weight (mg)	7.34±0.05 <sup>b</sup>	8.63±0.07 <sup>a</sup>	8.51±0.09 <sup>a</sup>	7.26±0.05 <sup>b</sup>
WG	1.76±0.02 <sup>b</sup>	2.97±0.04 <sup>a</sup>	2.91±0.13 <sup>a</sup>	1.74±0.05 <sup>b</sup>
WG%	31.5±0.84 <sup>b</sup>	52.54±0.81 <sup>a</sup>	52.13±2.97 <sup>a</sup>	31.6±1.15 <sup>b</sup>
SGR%	0.91±0.02 <sup>b</sup>	1.41±0.02 <sup>a</sup>	1.4±0.07 <sup>a</sup>	0.92±0.03 <sup>b</sup>

Different lowercase letters in each row indicate statistically significant differences between treatments ( $p<0.05$ ).

### Intestine morphology

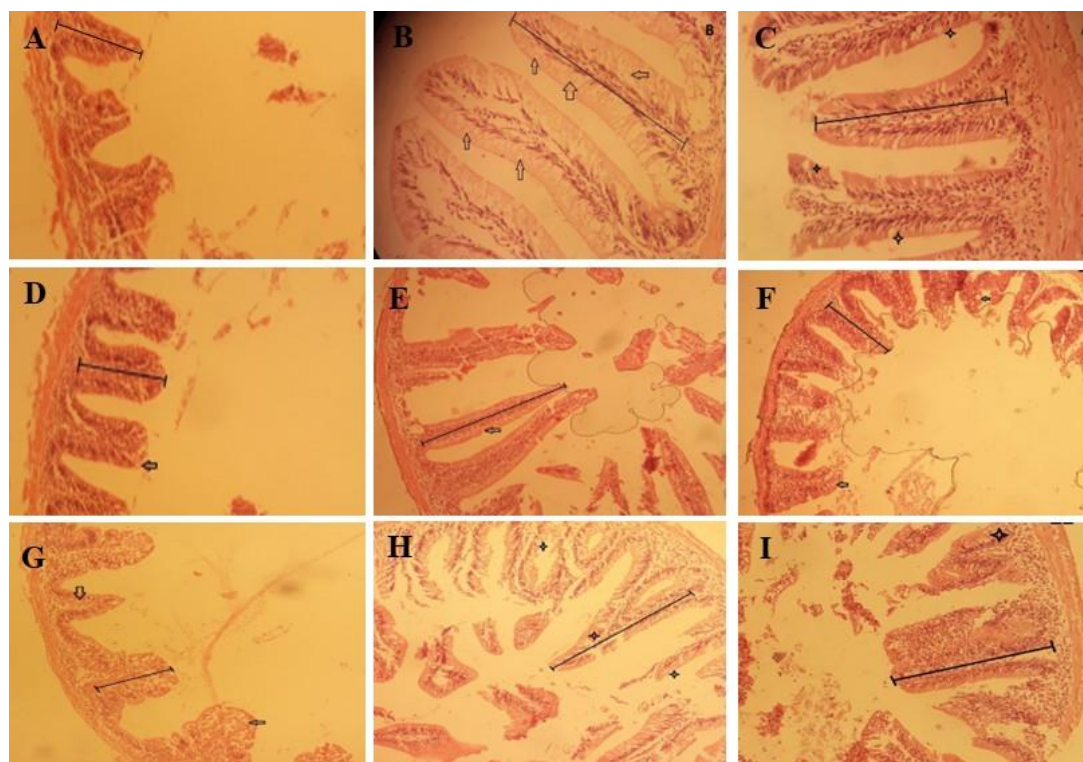
Table 2 presents the results of intestinal histology in koi fish fed with OEO and exposed to NPX on different days (0, 30, 37, and 44). The results indicated that feeding with OEO (in OE and OE+NAP treatments) had a significant effect on

the length and diameter of villi as well as the number of goblet cells. These changes were particularly significant after exposure to NPX in the OE+NAP group when compared to the NAP group ( $p<0.05$ ) (Fig. 1).

**Table 2: Examination of Villi Length and Diameter and Goblet Cell Count in the Intestines of Koi Fish Fed with OEO and Exposed to NPX.**

Day	Treatment	Villus height (µm)	Villus width (µm)	Number of goblet cells
0	NAP	110.51±7.2 <sup>a</sup>	24.79±3.6 <sup>a</sup>	2.98±2.12 <sup>a</sup>
	OE+NAP	109.92±4.6 <sup>a</sup>	26.32±14.1 <sup>a</sup>	2.52±1.08 <sup>a</sup>
	OE	113.2±6.2 <sup>a</sup>	25.94±4.8 <sup>a</sup>	4.11±3.09 <sup>a</sup>
	C	107.91±9.1 <sup>a</sup>	21.9±2.2 <sup>a</sup>	2.13±1.38 <sup>a</sup>
30	NAP	118.32±9.8 <sup>b</sup>	23.42±13.1 <sup>b</sup>	2.13±1.38 <sup>b</sup>
	OE+NAP	153.06±34.7 <sup>a</sup>	27.6±5.1 <sup>a</sup>	9.28±9.01 <sup>a</sup>
	OE	156.24±31.4 <sup>a</sup>	30.85±9.8 <sup>a</sup>	7.67±7.2 <sup>a</sup>
	C	121.54±12.4 <sup>b</sup>	26.85±10.8 <sup>b</sup>	3.78±3.09 <sup>b</sup>
37	NAP	138.52±9.3 <sup>b</sup>	24.84±4.5 <sup>b</sup>	5.06±3.21 <sup>c</sup>
	OE+NAP	170.52±20.6 <sup>a</sup>	27.81±7.9 <sup>a</sup>	13.16±8.43 <sup>a</sup>
	OE	178.08±35.2 <sup>a</sup>	31.4±9.8 <sup>a</sup>	8.42±7.31 <sup>b</sup>
	C	142.52±13.8 <sup>b</sup>	26.96±8.1 <sup>b</sup>	3.03±1.27 <sup>c</sup>
44	NAP	156.21±5.8 <sup>c</sup>	25.45±13.6 <sup>b</sup>	4.63±2.06 <sup>c</sup>
	OE+NAP	185.05±29.04 <sup>b</sup>	28.51±8.5 <sup>a</sup>	12.81±8.38 <sup>a</sup>
	OE	214.87±26.2 <sup>a</sup>	30.92±13.3 <sup>a</sup>	7.98±6.87 <sup>b</sup>
	C	161.21±12.8 <sup>c</sup>	25.72±9.3 <sup>b</sup>	3.49±1.58 <sup>c</sup>

Different lowercase letters in each row indicate statistically significant differences between treatments ( $p<0.05$ ).



**Figure 1: Comparison of Villi Length, Diameter, and Goblet Cell Count in the Intestine of Koi Fish Fed with OEO on Days 30, 37, and 44 (400x) - 1. Panels A, D, and G: CRT treatment. Panels B, E, and H: OE treatment. Panels C, F, and I: OE+NAP treatment.**

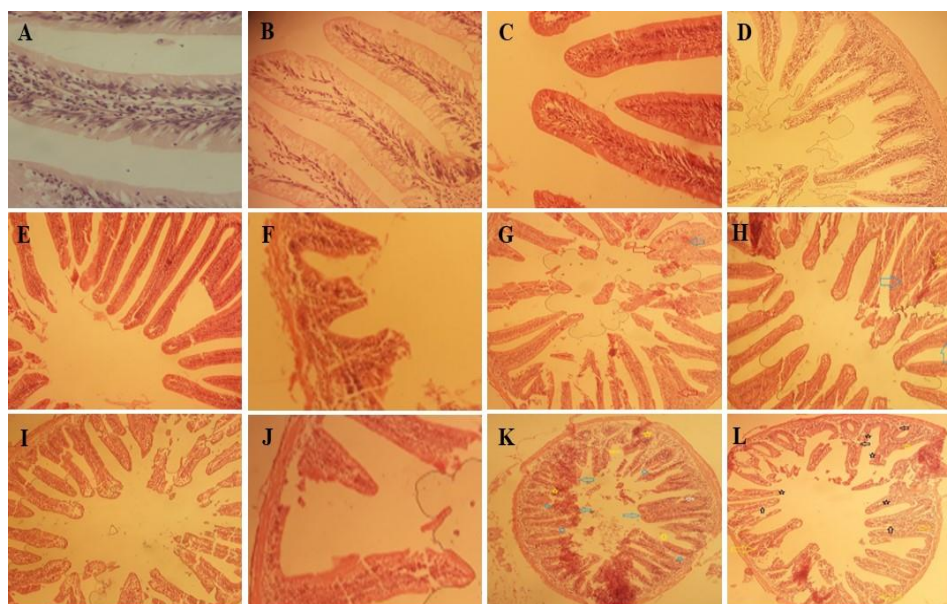
### *Intestine histopathology*

Figure 2 presents the histopathological lesions of intestinal tissue in koi fish fed OEO and exposed to NPX on different days (30, 37, and 44). The results showed that the fish in the CRT group had normal and healthy intestines, while the most tissue damage was observed in the liver tissue of the fish under poisoning treatments (OE+NAP and NAP) on the 37th and 44th days. The most commonly observed complications in these treatments included villous corruption, vacuolization, cell necrosis, toothbrush villi sticking, and hyperemia. Similar complications were observed in the NAP group on days 37 and 44, including villous corruption, vacuolization, cell necrosis, hyperemia, and toothbrush villi sticking. However,

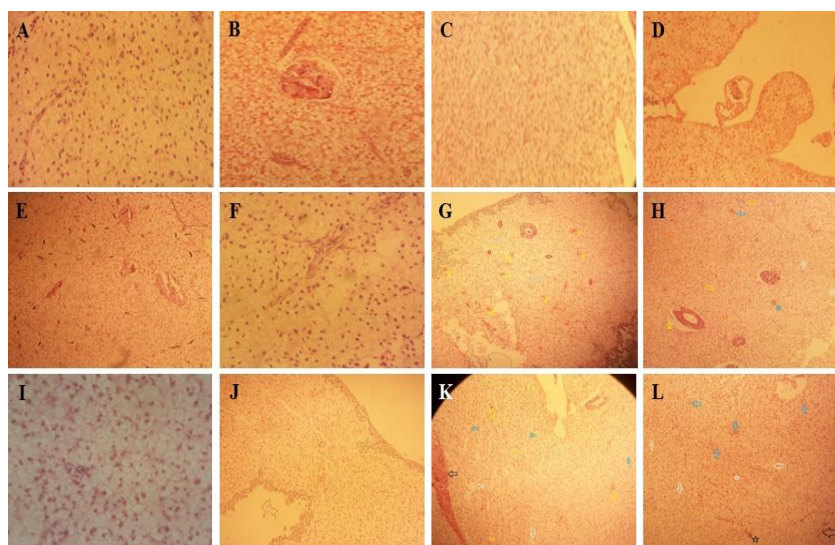
these complications were observed to have a less destructive effect in the OE+NAP treatment.

### *Liver histopathology*

Figure 3 presents the histopathological lesions of liver tissue in koi fish fed with OEO and exposed to NPX on different days (30, 37, and 44). The results showed that the fish in the CRT group had normal and healthy livers. The most tissue damage was observed in the liver tissue of the fish under poisoning treatments (OE+NAP and NAP) on the 37th and 44th days. The most commonly observed complications in these treatments included atrophy, fat, and necrosis, dilution of the sinusoid, dark granules, swelling, blood embolism, bleeding, and fluid.



**Figure 2: Histopathological Lesions of Liver Tissue in Koi Fish Fed with OEO and Exposed to NPX on Different Days (400x).** Panels A, B, C, and D: Day 30 - CRT, OE, OE+NAP, and NAP treatments, respectively, showing normal tissue. Panels E and F: Day 37 - CRT and OE treatments, respectively, showing normal tissue. Panels G and H: Day 37 - OE+NAP and NAP treatments, respectively, showing toothbrush villi sticking (red and blue arrows) and hyperemia (blue and yellow stars). Panels I, J, K, and L: Day 44 - CRT, OE, OE+NAP, and NAP treatments, respectively. Panel K shows toothbrush villi sticking (blue arrow), corruption of villi (yellow arrow), vacuolization (white arrow), hyperemia (star), and necrosis (hexagon). Panel L shows toothbrush villi sticking (yellow arrow), necrosis (black arrow), hyperemia (yellow star) and vacuolation (black star).



**Figure 3: Histopathological Complications of Liver Tissue in Koi Fish Fed with OEO and Exposed to NPX on Different Days (400x).** Panels A, B, C, and D: Day 30 - CRT, OE, OE+NAP, and NAP treatments, respectively, showing normal tissue. Panels E and F: Day 37 - CRT and OE treatments, respectively, showing normal tissue. Panels G and H: Day 37 - OE+NAP and NAP treatments, respectively, showing bleeding (yellow star and blue arrow), necrosis (red and white arrows), swelling (gray and orange arrows), and dark granule (blue star). Panels I, J, K, and L: Day 44 - CRT, OE, OE+NAP, and NAP treatments, respectively. Panel K shows fluid (white arrow), gallbladder swelling (black arrow), necrosis (blue arrow), blood occlusion (yellow arrow), swelling (green star), and fat (yellow hexagon). Panel L shows dilution of the sinusoid (black arrow), necrosis (white arrow), atrophy (blue arrow), and dark granule (white star).

The highest destructive effect was observed on the 37th day in the NAP group treatment, with complications such as atrophy, fluid, dark granules, and bleeding. These complications had a less destructive effect in the OE+NAP treatments, and in some cases, no destructive effect was observed.

## Discussion

In recent years, researchers have been fascinated by the positive effects of plant essential oils used in aquaculture (Kazempoor *et al.*, 2022). While several studies have investigated the effects of feeding aquatic animals with plant essential oils on growth (Dawood *et al.*, 2022), few have explored their potential in reducing damage caused by poisoning, particularly drug residues. In recent years, there have been numerous reports of water contamination with pharmaceutical compounds, making this issue one of the most pressing environmental concerns worldwide (Sundararaman *et al.*, 2022). Therefore, this study aimed to investigate, for the first time, the effects of feeding koi fish with OEO on growth and the reduction of intestinal and liver tissue damage during long-term exposure to NPX.

The results of this study showed that feeding Koi fish with OEO significantly improved their growth performance. This is consistent with previous reports of increased fish growth resulting from feeding with plant essential oils, such as oregano. Magouz *et al.* (2022) and Shourbela *et al.* (2021) reported weight gain in Nile tilapia (*Oreochromis niloticus*) after feeding with OEO, while

Abdel-Latif *et al.* (2020) reported an increase in the weight of common carp (*Cyprinus carpio*) fed with OEO. The improved growth of fish fed with plant essential oils is thought to be related to improved feed taste (Abdel-Latif and Khalil, 2014), enhanced intestinal microbial flora (Ran *et al.*, 2016), and increased secretion of digestive enzymes (Zhang *et al.*, 2020). According to Rashidian *et al.* (2021), the high levels of polyphenols and flavonoids in OEO are responsible for its positive effects on growth performance. However, further research is needed to fully understand the mechanisms by which OEO promotes the growth process of Koi fish.

In this study, OEO supplementation significantly increased the length and width of villi and the number of goblet cells in the intestines of Koi fish. Similar findings have been reported in Nile tilapia (Magouz *et al.*, 2022) and common carp (Abdel-Latif *et al.*, 2020), where OEO supplementation increased the length and width of intestinal villi. OEO's potential ability to improve the intestinal microbial flora of fish is thought to be responsible for this effect (Zhang *et al.*, 2020). Improvement in intestinal microbial flora increases beneficial bacteria and the production of short-chain fatty acids from sugars in the digestive system. Fatty acids are the primary energy sources of intestinal epithelial cells, and therefore play an important role in increasing the length and width of intestinal villi (Alavinezhad *et al.*, 2020).

The intestine is one of the most sensitive internal organs of fish exposed

to naproxen, and the side effects of NSAIDs occur in the digestive system (Stancová *et al.*, 2015). The results of this study showed that exposure to NPX caused lesions such as vacuolation, villi corruption, hyperemia, adhesion of toothbrush villi, and cell necrosis in the intestinal tissue of koi fish. Similar results have been reported in previous studies where fish were exposed to NSAID drugs (Hagiwara *et al.*, 2004; Watanabe *et al.*, 2008). The occurrence of lesions in the intestine can be caused by the negative effect of NSAIDs on the intestinal microbiota (Whitfield-Cargile *et al.*, 2016). However, the histopathological lesions in the intestines of fish fed with OEO were reduced, possibly due to the improvement of the intestinal microbial flora of fish fed with this essential oil. Zhang *et al.* (2020) reported the improvement of the microbial flora of the gastrointestinal tract of koi fish fed with OEO, although further investigation is needed to fully understand this mechanism.

The liver is the main metabolizing organ of the body, which participates in the process of detoxification and biotransformation. It plays a crucial role in the defense against drugs and toxins (Nunes *et al.*, 2014). The toxic effects of chemicals are mainly observed in the liver (Yildirim *et al.*, 2006), and therefore, it provides important information about the toxic effects and performance of chemical compounds in fish (Fontainhas-Fernandes *et al.*, 2008). This study observed lesions such as fluid, dark granules, dilution of the

sinusoid, hemorrhage, blood embolism, fattening, and swelling in the liver tissue of fish exposed to NPX. Similar histopathological lesions have been reported in previous studies with zebrafish exposed to NPX (Stancová *et al.*, 2015), diclofenac-exposed common carp (Mohebi Derakhsh *et al.*, 2020), and ketophen-exposed zebrafish (Rangasamy *et al.*, 2018). The observed liver lesions in Koi fish are caused by several factors, including abnormal accumulation of triglycerides and other lipids, which may lead to the formation of vacuoles in liver cells and are associated with necrosis and tissue damage (Kelly and Janz, 2009). Sinus expansion can also be a defense mechanism in fish to dilute the poison in the blood and strengthen the immune system (Mohebi Derakhsh *et al.*, 2020).

Feeding Koi fish with OEO reduced histopathological lesions in the liver of fish exposed to NPX. Several studies have reported the positive effects of feeding with essential oils on the reduction of histopathological liver lesions in fish exposed to small concentrations of toxins (Rafieepour *et al.*, 2019; Dawood *et al.*, 2020). The protective role of OEO in reducing liver tissue damage is related to its antioxidant properties and its ability to eliminate ROS produced during oxidative stress caused by exposure to NPX. NPX poisoning causes oxidative stress (Stancová *et al.*, 2015), and feeding with a diet containing OEO improves antioxidant performance in fish (Shourbela *et al.*, 2021). Therefore, investigating effective immune

mechanisms to reduce histopathological lesions in internal organs, including the intestine and liver of fish, after exposure to NPX and feeding with OEO, should be a topic of interest for future studies.

### **Conclusion**

The widespread use of NPX has led to pollution in surface waters, which has had adverse consequences on fish and other non-target organisms. Even small amounts of NPX pollution have caused tissue damage in the liver and intestinal organs of koi fish. The results of this study demonstrated that using OEO as a plant food supplement can improve growth performance, intestinal villi structure, and reduce histopathological lesions caused by exposure to NPX in the liver and intestine of fish. It is expensive and challenging to accurately estimate pharmaceutical pollutants, prevent their spread, and protect farmed aquatic animals in aquaculture environments. Therefore, using important compounds such as OEO as a suitable candidate in fish diets to reduce the effects of drugs is a recommended approach. OEO is a natural and cost-effective alternative to reduce the negative effects of NPX in fish, and it can potentially be used in other aquaculture species as well. However, further research is needed to determine the optimal dose and duration of OEO supplementation for different fish species and to fully understand the underlying mechanisms behind its beneficial effects.

### **Acknowledgement**

The authors would like to express their gratitude to Dr. Seyedeh Shiva Alavinejad, Department of Aquatic Health and Diseases, Faculty of Veterinary Medicine, University of Tehran, for her valuable assistance in the field. Her contributions have been instrumental in the successful completion of this study.

### **Declaration of Interest**

The authors declare that there are no conflicts of interest.

### **Ethical Statement**

The ethical statement of this study indicates that animal handling and tissue sampling procedures were carried out in accordance with the standard principles of laboratory animal care to minimize animal suffering. The study was approved by the local ethics committee of the Faculty of Science, Islamic Azad University, with reference number IR.IAU.SRB.REC.1400.038. This indicates that the study was conducted in compliance with ethical guidelines and regulations concerning the use of animals in research.

### **Data Availability**

The data presented in this study are available in this article.

### **References**

**Abdel-Latif, H.M. and Khalil, R.H., 2014.** Evaluation of two phytobiotics, *Spirulina platensis* and *Origanum vulgare* extract on growth, serum

- antioxidant activities and resistance of Nile tilapia (*Oreochromis niloticus*) to pathogenic *Vibrio alginolyticus*. *International Journal of Fisheries and Aquatic Studies*, 250, 250-255.
- Abdel-Latif, H.M., Abdel-Tawwab, M., Khafaga, A.F. and Dawood, M.A., 2020.** Dietary oregano essential oil improved the growth performance via enhancing the intestinal morphometry and hepatorenal functions of common carp (*Cyprinus carpio* L.) fingerlings. *Aquaculture*, 526, p.735432. <https://doi.org/10.1016/j.aquaculture.2020.735432>
- Aguiar, C.M., Chairez, I., Rodríguez, J.L., Tiznado, H., Santillán, R., Arrieta, D. and Poznyak, T., 2019.** Inhibition effect of ethanol in naproxen degradation by catalytic ozonation with NiO. *RSC advances*, 9(26), pp.14822-14833. <https://doi.org/10.1039/C9RA02133G>
- Alavinezhad, S.S., Kazempoor, R., Kakoolaki, S. and Anvar, S.A., 2020.** The effect of different concentrations of *Lacticaseibacillus casei* on the growth performance and intestinal morphology of zebrafish (*Danio rerio*). *Sustainable Aquaculture and Health Management Journal*, 6(2), pp. 60-70. <https://doi.org/10.52547/ijaah.6.2.60>
- Angiolillo, D.J. and Weisman, S.M., 2017.** Clinical pharmacology and cardiovascular safety of naproxen. *American Journal of Cardiovascular Drugs*, 17(2), 97-107. <https://doi.org/10.1016/j.chemosphere.2021.130688>
- Dawood, M.A., Metwally, A.E.S., Elkomy, A.H., Gewaily, M.S., Abdo, S.E., Abdel-Razek, M.A., Soliman, A.A., Amer, A.A., Abdel-Razik, N.I., Abdel-Latif, H.M. and Paray, B.A., 2020.** The impact of menthol essential oil against inflammation, immunosuppression, and histopathological alterations induced by chlorpyrifos in Nile tilapia. *Fish & Shellfish Immunology*, 102, pp.316-325. <https://doi.org/10.1016/j.fsi.2020.04.059>
- Dawood, M.A., El Basuni, M.F., Yilmaz, S., Abdel-Latif, H.M., Alagawany, M., Kari, Z.A., Abdul Razab, M.K.A., Hamid, N.K.A., Moonmanee, T. and Van Doan, H., 2022.** Exploring the roles of dietary herbal essential oils in aquaculture: A review. *Animals*, 12(7), 823 P. <https://doi.org/10.3390/ani12070823>
- FAO, 2018.** The state of world fisheries and aquaculture 2018—Meeting the sustainable development goals. Rome, Italy: The Food and Agricultural Organization of the United Nations. <http://www.fao.org/3/i9540en/i9540en.pdf>.
- Fontainhas-Fernandes, A., Luzio, A., Garcia-Santos, S., Carrola, J. and Monteiro, S., 2008.** Gill histopathological alterations in Nile tilapia, *Oreochromis niloticus* exposed to treated sewage

- water. *Brazilian Archives of Biology and Technology*, 51, pp. 1057-1063. <https://doi.org/10.1590/S1516-89132008000500023>
- Grabicová, K., Grabic, R., Fedorova, G., Staňová, A.V., Bláha, M., Randák, T., Brooks, B.W. and Žlábek, V., 2020.** Water reuse and aquaculture: Pharmaceutical bioaccumulation by fish during tertiary treatment in a wastewater stabilization pond. *Environmental Pollution*, 267, 115593 P. <https://doi.org/10.1016/j.envpol.2020.115593>
- Gruber, C., Ocelova, V., Kesselring, J.C. and Wein, S., 2025.** Phytogetic feed additives as a sustainable alternative to antibiotics: Enhancing growth and disease resistance in Nile tilapia (*Oreochromis niloticus*). *Animals*, 15(3), 380 P. <https://doi.org/10.3390/ani15030380>
- Hagiwara, M., Kataoka, K., Arimochi, H., Kuwahara, T. and Ohnishi, Y., 2004.** Role of unbalanced growth of gram-negative bacteria in ileal ulcer formation in rats treated with a nonsteroidal anti-inflammatory drug. *The Journal of Medical Investigation*, 51(1 and 2), pp. 43-51. <https://doi.org/10.2152/jmi.51.43>
- Justi, L.H.Z., Silva, J.F., Santana, M.S., Laureano, H.A., Pereira, M.E., Oliveira, C.S. and Guiloski, I.C., 2025.** Non-steroidal anti-inflammatory drugs and oxidative stress biomarkers in fish: A meta-analytic review. *Toxicology Reports*, 14, 101910 P. <https://doi.org/10.1016/j.toxrep.2025.101910>
- Kazempoor, R., Alavinezhad, S.S., Pargari, M.M., Shakeri, Y.S. and Haghghi, M.M., 2022.** A review on the application of phyto-genics as feed additives for aquatic animals. *International Journal of Aquatic Research and Environmental Studies*, 2(2), pp. 46-78. <https://doi.org/10.1016/j.envpol.2020.115593>
- Kelly, J.M., and Janz, D.M., 2009.** Assessment of oxidative stress and histopathology in juvenile northern pike (*Esox lucius*) inhabiting lakes downstream of a uranium mill. *Aquatic Toxicology*, 92(4), 240-249. <https://doi.org/10.1016/j.aquatox.2009.02.007>
- Li, Q., Wang, P., Chen, L., Gao, H. and Wu, L., 2016.** Acute toxicity and histopathological effects of naproxen in zebrafish (*Danio rerio*) early life stages. *Environmental Science and Pollution Research*, 23(18), pp.18832-18841. <https://doi.org/10.1007/s11356-016-7092-4>
- Madikizela, L.M. and Ncube, S., 2021.** Occurrence and ecotoxicological risk assessment of non-steroidal anti-inflammatory drugs in South African aquatic environment: What is known and the missing information?. *Chemosphere*, 280, 130688. <https://doi.org/10.1016/j.chemosphere.2021.130688>

- Magouz, F.I., Amer, A.A., Faisal, A., Sewilam, H., Aboelenin, S.M. and Dawood, M.A., 2022.** The effects of dietary oregano essential oil on the growth performance, intestinal health, immune, and antioxidative responses of Nile tilapia under acute heat stress. *Aquaculture*, 548, 737632 P.  
<https://doi.org/10.1016/j.aquaculture.2021.737632>
- Miller, T.H., Bury, N.R., Owen, S.F., MacRae, J.I. and Barron, L.P., 2018.** A review of the pharmaceutical exposome in aquatic fauna. *Environmental pollution*, 239, pp. 129-146.  
<https://doi.org/10.1016/j.envpol.2018.04.012>
- Mohebi Derakhsh, P., Mashinchian Moradi, A., Sharifpour, I. and Jamili, S., 2020.** Toxic effects of diclofenac on gills, liver and kidney of *Cyprinus carpio* (Linnaeus, 1758). *Iranian Journal of Fisheries Sciences*, 19(2), pp. 735-747.  
<https://dor.isc.ac/dor/20.1001.1.15622916.2020.19.2.21.5>
- Nunes, B., Miranda, A.F., Ozório, R.O.A., Gonçalves, F., Gonçalves, J.F.M. and Correia, A.T., 2014.** Modulation of neuronal activity and hepatic metabolism by ploidy and l-carnitine supplement in rainbow trout (*Oncorhynchus mykiss*). *Aquaculture nutrition*, 20(3), pp.242-252.  
<https://doi.org/10.1111/anu.12070>
- OECD, 1984.** Test No. 204: Fish, Prolonged Toxicity Test: 14-Day Study, OECD Guidelines for the Testing of Chemicals, Section 2, OECD Publishing, Paris, 1984.  
<http://dx.doi.org/10.1787/9789264069985-en>.
- Picinini-Zambelli, J., Garcia, A.L.H. and Da Silva, J., 2025.** Emerging pollutants in the aquatic environments: A review of genotoxic impacts. *Mutation Research-Reviews in Mutation Research*, 795, 108519 P.  
<https://doi.org/10.1016/j.mrrev.2024.108519>
- Rafiepour, A., Hajirezaee, S. and Rahimi, R., 2019.** Moderating effects of dietary oregano extract (*Origanum vulgare*) on the toxicity induced by organophosphate pesticide, diazinon in rainbow trout, *Oncorhynchus mykiss*: metabolic hormones, histology and growth parameters. *Turkish Journal of Fisheries and Aquatic Sciences*, 20(3), 207-219.  
[http://doi.org/10.4194/1303-2712-v20\\_3\\_05](http://doi.org/10.4194/1303-2712-v20_3_05)
- Ran, C., Hu, J., Liu, W., Liu, Z., He, S., Dan, B.C.T., Diem, N.N., Ooi, E.L. and Zhou, Z., 2016.** Thymol and carvacrol affect hybrid tilapia through the combination of direct stimulation and an intestinal microbiota-mediated effect: insights from a germ-free zebrafish model. *The Journal of nutrition*, 146(5), pp. 1132-1140.  
<https://doi.org/10.3945/jn.115.229377>
- Rangasamy, B., Hemalatha, D., Shobana, C., Nataraj, B. and Ramesh, M., 2018.** Developmental toxicity and biological responses of zebrafish (*Danio rerio*) exposed to

- anti-inflammatory drug  
ketoprofen. *Chemosphere*, 213, pp. 423-433.  
<https://doi.org/10.1016/j.chemosphere.2018.09.013>
- Rashidian, G., Boldaji, J.T., Rainis, S., Prokić, M.D. and Faggio, C., 2021. Oregano (*Origanum vulgare*) extract enhances zebrafish (*Danio rerio*) growth performance, serum and mucus innate immune responses and resistance against *Aeromonas hydrophila* challenge. *Animals*, 11(2), 299 P. <https://doi.org/10.3390/ani11020299>
- Sehonova, P., Svobodova, Z., Dolezelova, P., Vosmerova, P. and Faggio, C., 2018. Effects of waterborne antidepressants on non-target animals living in the aquatic environment: A review. *Science of the Total Environment*, 631, pp. 789-794.  
<https://doi.org/10.1016/j.scitotenv.2018.03.076>
- Shourbela, R.M., El-Hawarry, W.N., Elfadadny, M.R. and Dawood, M.A., 2021. Oregano essential oil enhanced the growth performance, immunity, and antioxidative status of Nile tilapia (*Oreochromis niloticus*) reared under intensive systems. *Aquaculture*, 542, 736868 P.  
<https://doi.org/10.1016/j.aquaculture.2021.736868>
- Stancová, V., Ziková, A., Svobodová, Z. and Kloas, W., 2015. Effects of the non-steroidal anti-inflammatory drug (NSAID) naproxen on gene expression of antioxidant enzymes in zebrafish (*Danio rerio*). *Environmental Toxicology and Pharmacology*, 40(2), pp.343-348.  
<https://doi.org/10.1016/j.etap.2015.07.009>
- Sundararaman, S., Kumar, J.A., Deivasigamani, P. and Devarajan, Y., 2022. Emerging pharma residue contaminants: Occurrence, monitoring, risk and fate assessment—A challenge to water resource management. *Science of the Total Environment*, 825, 153897 P. <https://doi.org/10.1016/j.scitotenv.2022.153897>
- Watanabe, T., Higuchi, K., Kobata, A., Nishio, H., Tanigawa, T., Shiba, M., Tominaga, K., Fujiwara, Y., Oshitani, N., Asahara, T. and Nomoto, K., 2008. Non-steroidal anti-inflammatory drug-induced small intestinal damage is Toll-like receptor 4 dependent. *Gut*, 57(2), pp. 181-187.  
<https://doi.org/10.1136/gut.2007.125963>
- Whitfield-Cargile, C.M., Cohen, N.D., Chapkin, R.S., Weeks, B.R., Davidson, L.A., Goldsby, J.S., Hunt, C.L., Steinmeyer, S.H., Menon, R., Suchodolski, J.S. and Jayaraman, A., 2016. The microbiota-derived metabolite indole decreases mucosal inflammation and injury in a murine model of NSAID enteropathy. *Gut Microbes*, 7(3), pp.246-261.  
<https://doi.org/10.1080/19490976.2016.1156827>

- Wojcieszynska, D. and Guzik, U., 2020.** Naproxen in the environment: its occurrence, toxicity to nontarget organisms and biodegradation. *Applied Microbiology and Biotechnology*, 104(5), 1849-1857. <https://doi.org/10.1007/s00253-019-10343-x>
- Xu, C., Niu, L., Guo, H., Sun, X., Chen, L., Tu, W., Dai, Q., Ye, J., Liu, W. and Liu, J., 2019.** Long-term exposure to the non-steroidal anti-inflammatory drug (NSAID) naproxen causes thyroid disruption in zebrafish at environmentally relevant concentrations. *Science of the Total Environment*, 676, pp. 387-395. <https://doi.org/10.1016/j.scitotenv.2019.04.323>
- Yildirim, M.Z., Benli, A.Ç.K., Selvi, M., Özkul, A., Erkoc, F. and Kocak, O., 2006.** Acute toxicity, behavioral changes, and histopathological effects of deltamethrin on tissues (gills, liver, brain, spleen, kidney, muscle, skin) of Nile tilapia (*Oreochromis niloticus* L.) fingerlings. *Environmental Toxicology: An International Journal*, 21(6), pp. 614-620. <https://doi.org/10.1002/tox.20225>
- Zhang, R., Wang, X.W., Liu, L.L., Cao, Y.C. and Zhu, H., 2020.** Dietary oregano essential oil improved the immune response, activity of digestive enzymes, and intestinal microbiota of the koi carp, *Cyprinus carpio*. *Aquaculture*, 518, 734781 P.